



Online article and related content
current as of February 9, 2010.

Serial 2-Point Ultrasonography Plus D-Dimer vs Whole-Leg Color-Coded Doppler Ultrasonography for Diagnosing Suspected Symptomatic Deep Vein Thrombosis: A Randomized Controlled Trial

Enrico Bernardi; Giuseppe Camporese; Harry R. Büller; et al.

JAMA. 2008;300(14):1653-1659 (doi:10.1001/jama.300.14.1653)

<http://jama.ama-assn.org/cgi/content/full/300/14/1653>

Correction	Contact me if this article is corrected.
Citations	This article has been cited 10 times. Contact me when this article is cited.
Topic collections	Venous Thromboembolism; Cardiovascular System; Radiologic Imaging; Randomized Controlled Trial; Diagnosis; Ultrasonography Contact me when new articles are published in these topic areas.
Related Articles published in the same issue	Noninvasive Diagnosis of Deep Vein Thrombosis C. Seth Landefeld. <i>JAMA</i>. 2008;300(14):1696. Thrombophlebitis Janet M. Torpy et al. <i>JAMA</i>. 2008;300(14):1718.
Related Letters	Ultrasound-Based Diagnostic Strategies for Deep Vein Thrombosis Isabelle Quere et al. <i>JAMA</i>. 2009;301(9):933. Frederikus A. Klok et al. <i>JAMA</i>. 2009;301(9):933. In Reply: Enrico Bernardi et al. <i>JAMA</i>. 2009;301(9):934.

Subscribe
<http://jama.com/subscribe>

Permissions
permissions@ama-assn.org
<http://pubs.ama-assn.org/misc/permissions.dtl>

Email Alerts
<http://jamaarchives.com/alerts>

Reprints/E-prints
reprints@ama-assn.org

Serial 2-Point Ultrasonography Plus D-Dimer vs Whole-Leg Color-Coded Doppler Ultrasonography for Diagnosing Suspected Symptomatic Deep Vein Thrombosis

A Randomized Controlled Trial

Enrico Bernardi, MD, PhD

Giuseppe Camporese, MD

Harry R. Büller, MD, PhD

Sergio Siragusa, MD

Davide Imberti, MD

Arrigo Berchio, MD

Angelo Ghirarduzzi, MD

Fabio Verlato, MD

Raffaella Anastasio, MD

Carolina Prati, MD

Andrea Piccioli, MD

Raffaele Pesavento, MD

Carlo Bova, MD

Patrizia Maltempo, MD

Nello Zanatta, MD

Alberto Cogo, MD, PhD

Roberto Cappelli, MD

Eugenio Bucherini, MD

Stefano Cuppini, MD

Franco Noventa, MD

Paolo Prandoni, MD, PhD

for the Erasmus Study Group

Context Patients with suspected deep vein thrombosis (DVT) of the lower extremities are usually investigated with ultrasonography either by the proximal veins (2-point ultrasonography) or the entire deep vein system (whole-leg ultrasonography). The latter approach is thought to be better based on its ability to detect isolated calf vein thrombosis; however, it requires skilled operators and is mainly available only during working hours. No randomized comparisons are yet available evaluating the relative values of these 2 strategies.

Objective To assess if the 2 diagnostic strategies are equivalent for the management of symptomatic outpatients with suspected DVT of the lower extremities.

Design, Setting, and Patients A prospective, randomized, multicenter study of consecutive symptomatic outpatients (n=2465) with a first episode of suspected DVT of the lower extremities who were randomized to undergo 2-point or whole-leg ultrasonography. Data were taken from ultrasound laboratories of 14 Italian universities or civic hospitals between January 1, 2003, and December 21, 2006. Patients with normal ultrasound findings were followed up for 3 months, with study completion on March 20, 2007.

Main Outcome Measure Objectively confirmed 3-month incidence of symptomatic venous thromboembolism in patients with an initially normal diagnostic workup.

Results Of 2465 eligible patients, 345 met 1 or more exclusion criteria and 22 refused to participate; therefore, 2098 patients were randomized to either 2-point (n=1045) or whole-leg (n=1053) ultrasonography. Symptomatic venous thromboembolism occurred in 7 of 801 patients (incidence, 0.9%; 95% confidence interval [CI], 0.3%-1.8%) in the 2-point strategy group and in 9 of 763 patients (incidence, 1.2%; 95% CI, 0.5%-2.2%) in the whole-leg strategy group. This met the established equivalence criterion (observed difference, 0.3%; 95% CI, -1.4% to 0.8%).

Conclusion The 2 diagnostic strategies are equivalent when used for the management of symptomatic outpatients with suspected DVT of the lower extremities.

Trial Registration clinicaltrials.gov Identifier: NCT00353093

JAMA. 2008;300(14):1653-1659

www.jama.com

COMPRESSION ULTRASONOGRAPHY¹ is a highly accurate method for the detection of deep vein thrombosis (DVT) in symptomatic outpatients² and has replaced ascending venography and other diagnostic methods in common practice.³

See also p 1696 and Patient Page.

Usually,^{2,8} only the proximal veins are investigated; namely, compression is applied to the common femoral vein at the groin and the popliteal vein at the popliteal fossa (2-point ultrasonography). Relevant features of this strategy are simplicity (may be proficiently learned in <2 hours⁹), reproducibility,⁴ and broad availability (may be performed with virtually all ultrasound scanners, irrespec-

tive of age, model, and even of the probe frequency). Its major limitation is the need to repeat the test once within 1 week in patients with normal findings

Author Affiliations and the Erasmus Study Group Members are listed at the end of this article.

Corresponding Author: Enrico Bernardi, MD, PhD, Pronto Soccorso, Dipartimento di Scienze Chirurgiche, Ospedale di Conegliano, Via Brigata Bisagno 4, Conegliano, 31015 Italy (enrico.bernardi@ulss7.it).

at presentation to detect calf DVT extending to the proximal veins (serial 2-point ultrasonography).²⁻⁸ Repeat testing may be safely avoided in patients with a normal D-dimer test result at presentation.^{6-8,10,11}

The newer color-coded Doppler ultrasound scanners allow the evaluation of the entire deep venous system, from the groin to the ankle (whole-leg ultrasonography). With this strategy, color flow artifacts are exploited to enhance small vessel visualization, although vein compressibility still constitutes the main diagnostic criterion. The advantage of this approach is the ability to exclude isolated calf DVT, allowing for 1-day treatment of all patients, without additional testing.¹²⁻¹⁵ Conversely, it needs top-quality ultrasound equipment and experienced operators; therefore, it is often unobtainable after hours and during the weekends.^{16,17}

Despite the lack of definite evidence, whole-leg ultrasonography is thought to be better than serial 2-point ultrasonography, especially in the everyday practice of ultrasound laboratories, based on the assumption that detecting isolated calf DVT is a clinically relevant issue.^{18,19} As a consequence, many patients with suspected DVT need to wait hours or even days before whole-leg ultrasonography is obtained^{16,17} and are frequently (unnecessarily) administered anticoagulants in the meantime.^{16,20}

Recent observations challenge this view and claim that prompt detection of calf DVT may not be as relevant as previously believed.²¹⁻²⁴ Conversely, the systematic evaluation of the calf vein system may bring about a definite risk of overtreating thrombi that may otherwise heal spontaneously.^{15,25}

To test the hypothesis that the 2 diagnostic strategies are equivalent for the exclusion of a first episode of suspected DVT in symptomatic outpatients, we undertook a prospective, randomized, multicenter study assessing the incidence of symptomatic venous thromboembolism (VTE) during a 3-month follow-up period in patients spared anticoagulation on the basis of a normal initial workup with either se-

rial 2-point ultrasonography plus D-dimer (2-point strategy) or whole-leg color-coded Doppler ultrasonography (whole-leg strategy).

METHODS

Patients

All consecutive outpatients who were referred by the emergency department or a primary care physician to 1 of the 14 study centers (all ultrasound laboratories located in Italy) with a first episode of suspected symptomatic DVT of the lower extremities were eligible for inclusion. Exclusion criteria included pregnancy, age younger than 18 years, history of VTE, suspected pulmonary embolism, life expectancy of less than 3 months, ongoing anticoagulation (>48 hours), mandatory indication for anticoagulation (eg, atrial fibrillation), and geographic inaccessibility to follow-up. Patients were enrolled between January 1, 2003, and December 21, 2006, with study completion on March 20, 2007. The study was conducted according to the ethical principles stated in the Declaration of Helsinki, and the protocol was approved by the institutional review board of each participating center.

Randomization

Eligible patients, after signing a written informed consent form, were assigned to either the 2-point or the whole-leg strategy. The investigators had to contact the coordinating center by telephone to obtain the patient's group allocation. A randomization list was available for each center, arranged by blocks of 10 patients to ensure balancing (generated by nQuery functionality [nQuery Advisor; Statistical Solutions Ltd, Cork, Ireland]).

Study Outline

Two-Point Strategy. Patients with normal ultrasound findings at presentation underwent D-dimer testing. Patients with normal D-dimer levels were spared further investigation and were not anticoagulated. Patients with abnormal D-dimer levels were scheduled for a repeat ultrasonography at 1

week, or earlier if clinically indicated. Those patients with normal repeat ultrasound findings were spared further investigation and were not anticoagulated.

Whole-Leg Strategy. Patients with normal ultrasound results at presentation were spared further investigation and were not anticoagulated.

Follow-up. Patients with normal findings at the initial diagnostic workup were scheduled for an end of follow-up visit after 3 months, which consisted of (1) a standardized interview to assess their general health status, chest or leg complaints, and history of hospital admission for any cause; (2) a physical examination; and (3) an ultrasonographic evaluation. Patients were instructed to refer to the study centers immediately if they experienced syncope, shortness of breath, chest pain, palpitations, and either new or worsening leg symptoms. Patients who did not attend the scheduled visit were contacted by telephone by the investigators and interviewed using a standardized questionnaire to assess their general health status, chest or leg complaints, and history of hospital admission for any cause.

Interventions

All diagnostic evaluations were performed by certified physicians with long-standing experience in vascular ultrasonography.

Two-Point Strategy. Two-point ultrasonography was performed and interpreted as described elsewhere.²⁻⁴ Briefly, the common femoral at the groin and the popliteal vein down to its branching into the calf deep veins at the popliteal fossa were examined in the transverse plane with a linear probe (5-10 MHz). Vein incompressibility was the only diagnostic criterion applied. Test results were categorized as normal (compressible veins) or abnormal (noncompressible veins).

D-dimer testing was evaluated by using a rapid whole-blood bedside D-dimer assay (SimpliRED D-Dimer; AGEN Biomedical Ltd, Brisbane, Australia), which was based on red blood

cells agglutination.²⁶ Results were categorized as normal (no visible agglutination) or abnormal (visible agglutination or noninterpretable findings).

Whole-Leg Strategy. Lacking a widely accepted protocol for whole-leg ultrasonography, the standard procedure for the study purposes was agreed a priori by all investigators during a consensus meeting held before the beginning of the study. All veins were imaged continuously along their length, in the transverse plane, with a linear probe (5-10 MHz). The proximal deep veins were examined first, including the femoral veins (common, superficial, and deep) and the popliteal vein down to its trifurcation. Then, only in patients with normal proximal findings, the calf veins were evaluated, including the axial (peroneal and posterior tibial) and the muscular veins. Vein incompressibility was the sole diagnostic criterion adopted for abnormal testing of the proximal and axial calf veins. Adjunctive criteria for abnormal testing of the muscular veins only included lack of spontaneous or reverse-flow intraluminal color-filling after augmentation maneuvers (ie, manual squeezing of the calf).

Main Outcome Measure

We assessed the incidence of objectively proven symptomatic VTE occurring during a 3-month follow-up period in patients with normal findings at the initial diagnostic workup, with either of the 2 diagnostic strategies.

End Point Adjudication

All suspected symptomatic events were to be evaluated as follows. Deep vein thrombosis was confirmed by abnormal findings on compression ultrasonography or venography, and pulmonary embolism was confirmed by abnormal computed tomography, high probability ventilation-perfusion lung scanning, or abnormal pulmonary angiography. Fatal pulmonary embolism was adjudicated by autopsy, or on clinical grounds in case of sudden and otherwise inexplicable death, according to the opinion of an independent physician. An independent and blind

committee adjudicated the suspected thromboembolic events based on all relevant documents and footage.

Sample Size Calculation and Statistical Analysis

As specified in the study protocol, the investigation was designed to determine whether the 2 strategies would have similar safety (ie, as an equivalence study). The observed cumulative incidence of symptomatic VTE events during follow-up after a normal workup with either the 2-point or whole-leg strategy is around 1%.^{3-9,12-16} To be conservative, we assumed that both strategies would be equally accurate^{1-3,27,28}; however, as only whole-leg ultrasonography is able to detect calf DVT, a lower incidence of VTE events would be expected during follow-up in this group. We specified that the 2 strategies would be clinically equivalent if the upper boundary of the 95% confidence interval (CI) around the difference between the proportion of events in the 2 groups at the end of follow-up was within 1.5%. We calculated that a sample size of 796 patients in each group would satisfy these requirements, with an 80% power if the proportion of events during the 3-month follow-up was 1% in both groups.²⁹ Assuming an initial prevalence of DVT of up to 25%, we calculated that we needed to enroll at least 1050 patients in each group.

Sample size was estimated by nQuery Advisor version 5.0 (Statistical Solutions Ltd). The binomial distribution was used to determine 95% CI for proportions. To account for patients who were lost and/or died during follow-up, we performed a sensitivity analysis. Statistical analyses were performed by using SPSS statistical software version 15.0 (SPSS Inc, Chicago, Illinois).

RESULTS

Patients

Of 2465 eligible patients with suspected DVT, 345 were excluded because the patients did not meet inclusion criteria and 22 refused to participate (FIGURE). Consequently, 2098 pa-

tients were randomized to either the 2-point strategy (n=1045) or the whole-leg strategy (n=1053). TABLE 1 shows the demographic and clinical characteristics of the study patients at entry.

Initial Prevalence of DVT

Of 1045 patients randomized to the 2-point strategy, 231 (22.1%; 95% CI, 19.6%-24.6%) had abnormal findings at the initial diagnostic workup; by definition, all events were proximal DVT. A total of 217 patients (20.8%) had abnormal ultrasound findings at presentation, and 828 had normal test results and underwent D-dimer testing. D-dimer testing results were abnormal in 256 of 828 patients (30.9%) who were scheduled for repeat ultrasonography within 1 week. During the week, none of these 256 patients received antithrombotic drugs and none developed signs or symptoms of pulmonary embolism; however, 17 patients presented for retesting during the week because of worsening leg symptoms (of these, 2 patients had abnormal ultrasound test results). Of the 239 patients with improved or unchanged leg symptoms who presented for repeat ultrasonography at the 1-week visit, 12 had abnormal findings. Thus, 14 of the 256 patients (5.5%) with abnormal D-dimer testing had abnormal repeat ultrasonography. The remaining 814 patients, which included 572 patients with normal D-dimer and 242 patients with abnormal D-dimer and normal serial ultrasonography, were not anticoagulated and were followed up for 3 months.

Of the 1053 patients randomized to the whole-leg strategy, 278 (26.4%; 95% CI, 23.7%-29.1%) had abnormal ultrasound findings at presentation. Of these, 213 patients (76.6%) had proximal DVT, 36 patients (13.0%) had isolated axial (posterior tibial or peroneal) DVT, and 29 patients (10.4%) had isolated muscular vein thrombosis. The remaining 775 patients with normal ultrasound findings were not anticoagulated and were followed up for 3 months.

Three-Month Follow-up

TABLE 2 shows the type, timing, diagnostic method used, and location of the

outcome events that occurred during the 3 months of follow-up. Of 814 patients allocated to the 2-point strategy, 9 (1.1%) died during follow-up, because of cancer (n=5), brain hemorrhage (n=1), ischemic stroke (n=1), myocardial infarction (n=1), and heart failure (n=1); and 4 patients (0.5%) were lost to follow-up (unknown

whereabouts). Sixteen patients had suspected symptomatic VTE during the follow-up period, which was objectively confirmed in 7 patients and not found in 9 patients. Therefore, in this group, the incidence of confirmed symptomatic VTE during the 3-month follow-up period was 0.9% (95% CI, 0.3%-1.8%). Of 785 patients eligible for the

clinical and instrumental end of follow-up visit, 189 (24%) regularly presented to the clinics and 596 (76%) were interviewed by telephone.

Of 775 patients randomized to the whole-leg strategy, 7 (0.9%) died during follow-up, because of cancer (n=5), massive trauma (n=1), and myocardial infarction (n=1); and 5 patients (0.6%) were lost to follow-up (unknown whereabouts). Twenty-one patients had suspected symptomatic VTE during the follow-up period, which was objectively confirmed in 9 patients and not found in 12 patients. Therefore, the incidence of confirmed symptomatic VTE during the 3-month follow-up period was 1.2% (95% CI, 0.5%-2.2%). Of 742 patients eligible for the clinical and instrumental end of follow-up visit, 172 (23%) regularly presented to the clinics and 570 (77%) were interviewed by telephone.

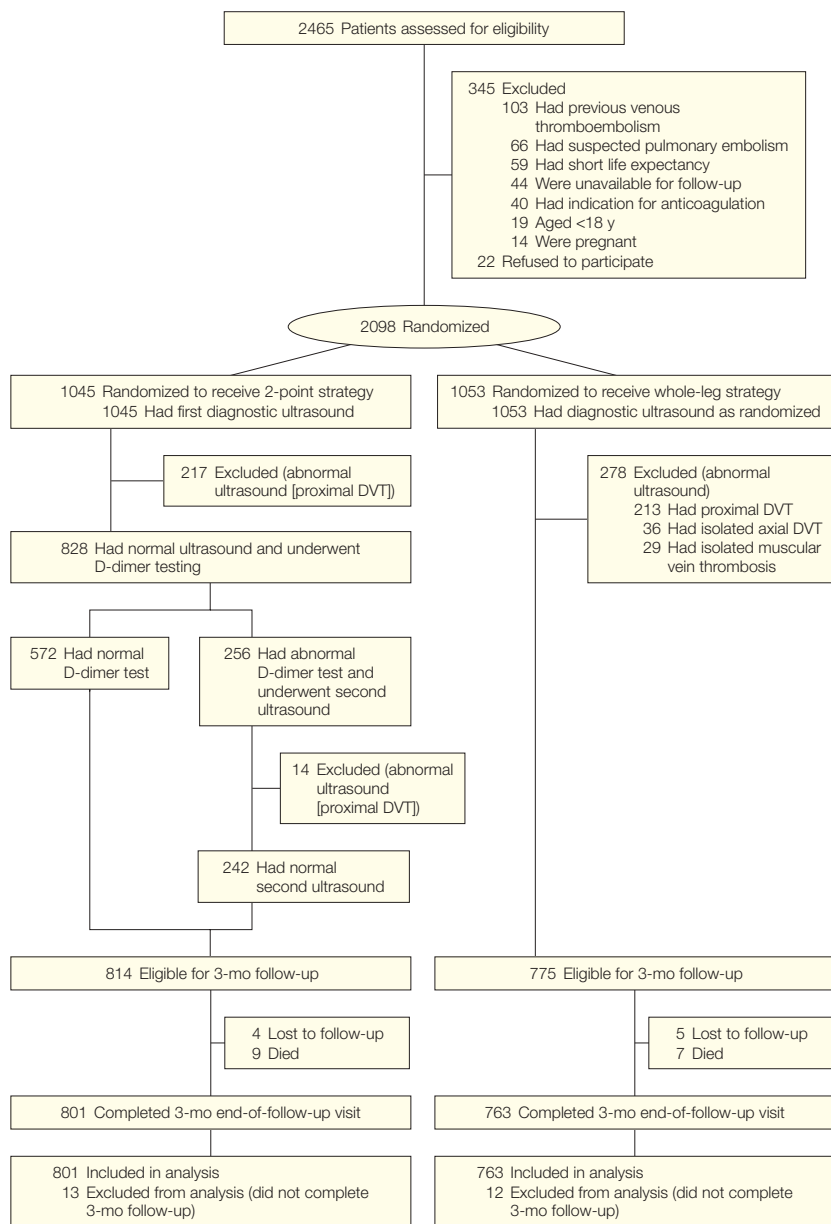
The observed difference between the 2 groups in terms of symptomatic VTE at the end of the 3-month follow-up period was 0.3% (95% CI, -1.4% to 0.8%), which is within the chosen equivalence limit. The sensitivity analysis, including patients who died during the study and/or were lost to follow-up, did not yield different results from the main analysis.

COMMENT

Our study shows that the 2-point and whole-leg strategies are equivalent for the management of symptomatic patients with suspected DVT. The 3-month incidence of objectively confirmed VTE in patients with an initial normal diagnostic ultrasound was similar in the 2 study groups. Furthermore, the observed data are consistent with those reported in previous large cohort studies.^{3-8,11-14}

Two specific issues deserve further discussion. First, despite a significantly higher initial prevalence of DVT in the whole-leg group compared with the 2-point group (absolute difference, 4.3%; 95% CI, 0.5%-8.1%), the long-term outcome of the patients was quite similar. Interestingly, that difference was entirely accounted for by 65

Figure. Flow of Study Patients



DVT, deep vein thrombosis. Two-point strategy indicates serial 2-point ultrasonography plus D-dimer; whole-leg strategy indicates whole-leg color-coded Doppler ultrasonography.

cases of isolated calf DVT identified by whole-leg ultrasonography; thus, one might speculate that detecting isolated calf DVT may not be as relevant as previously believed.^{11-14,25} However, because objectively diagnosed symptomatic calf DVT requires full anticoagulation,^{25,30} the quest for distal DVT might even expose patients to the harm of unnecessary treatment.^{15,21} This interesting hypothesis, previously suggested^{15,21-24} and still awaiting confirmation, is indirectly supported by the findings of a recent randomized trial¹¹ and of several cohort studies.¹²⁻¹⁴ In these studies, which routinely investigated the calf veins, the reported incidence of thromboembolic events after 3 to 6 months of follow-up in patients spared anticoagulants on the basis of a normal ultrasound is fully comparable with that observed in studies which did not investigate the calf veins.³¹ A properly designed randomized study is necessary to address this issue in a formally and scientifically correct fashion.

Second, the thorough evaluation of the femoral veins (common, superficial, or deep) and of the popliteal vein did not increase the overall diagnostic yield of the whole-leg strategy. The

initial prevalence of proximal DVT was similar in both groups (22.1% in the 2-point strategy group vs 20.2% in the whole-leg strategy group). This finding confirms that, in symptomatic outpatients, proximal DVT always involves the common femoral vein, the popliteal vein, or both; and there-

fore the superficial and deep femoral veins are usually not worth investigating.^{2,4,32}

Our results were obtained using adequate methods. All consecutive symptomatic patients referred to the participating centers were eligible for inclusion in the study. Confounding

Table 1. Demographic and Clinical Characteristics of the Study Patients at Presentation^a

	Two-Point Strategy (n = 1045)	Whole-Leg Strategy (n = 1053)
Demographic characteristics		
Age, mean (SD), y	63.7 (16.3)	62.5 (16.2)
Male sex, No. (%)	439 (42.0)	430 (40.8)
Obesity (BMI ≥30), No. (%)	157 (15.0)	165 (15.7)
Current smoker, No. (%)	93 (8.9)	74 (7.0)
Clinical characteristics		
Patient-physician delay, mean (SD), d ^b	7.14 (5.3)	7.14 (6.1)
Risk factors of thrombosis, No. (%)		
Cancer	292 (27.9)	315 (29.9)
Prolonged immobilization (≥7 d)	156 (14.9)	147 (14.0)
Surgery (≤4 wk)	154 (14.7)	126 (11.9)
Leg trauma or fracture, plaster cast	256 (24.5)	262 (24.9)
Paralysis or paresis	30 (2.9)	26 (2.5)
No. of women in pregnancy or puerperium ^c	8 (1.3)	11 (1.8)
No. of women receiving hormone therapy ^c	38 (6.3)	40 (6.4)
Heart failure	51 (4.9)	42 (4.0)
Long-distance travel (≥8 h)	20 (1.9)	11 (1.0)

Abbreviation: BMI, body mass index, calculated as weight in kilograms divided by height in meters squared.
^aTwo-point strategy indicates serial 2-point ultrasonography plus D-dimer; whole-leg strategy indicates whole-leg color-coded Doppler ultrasonography.
^bTime elapsed from onset of symptoms to patient presentation.
^cThe total number of women was 606 for 2-point strategy and 623 for whole-leg strategy.

Table 2. Distribution and Timing of Venous Thromboembolic Events

Allocation Group End Points ^a	Timing, d ^b	Diagnostic Method	DVT Site
Two-point strategy			
Ipsilateral DVT	10	Ultrasonography	Proximal
Ipsilateral DVT	12	Ultrasonography	Proximal
Ipsilateral DVT	12	Ultrasonography	Isolated calf
Ipsilateral DVT	21	Ultrasonography	Proximal
Ipsilateral DVT	66	Ultrasonography	Proximal
Contralateral DVT	68	Ultrasonography	Proximal
Ipsilateral DVT	81	Ultrasonography	Isolated calf
Whole-leg strategy			
Pulmonary embolism	2	V̇/Q lung scan and computed tomography	NA
Contralateral DVT	18	Ultrasonography	Isolated calf
Ipsilateral DVT	42	Ultrasonography	Proximal
Pulmonary embolism	48	V̇/Q lung scan	NA
Ipsilateral DVT	54	Ultrasonography	Proximal
Pulmonary embolism	68	Computed tomography	NA
Ipsilateral DVT	88	Ultrasonography	Proximal
Contralateral DVT	88	Ultrasonography	Proximal
Ipsilateral DVT	92	Ultrasonography	Isolated calf

Abbreviations: DVT, deep vein thrombosis; NA, not applicable; V̇/Q, ventilation-perfusion.
^aTwo-point strategy indicates serial 2-point ultrasonography plus D-dimer; whole-leg strategy indicates whole-leg color-coded Doppler ultrasonography.
^bDays from the beginning of follow-up.

factors were minimized by excluding patients with a history of previous VTE. Demographic characteristics and risk factors for DVT were evenly distributed in the 2 study groups. Patients randomized to the 2-point strategy were treated according to a highly standardized method.^{3,4,7,8} The D-dimer assay we used has a high reproducibility and negative predictive value in clinically symptomatic patients.^{10,26,33} Lacking a widely accepted protocol for whole-leg ultrasonography, all investigators agreed a priori the evaluation technique and the diagnostic criteria to be used. Only experienced physicians did ultrasonography. Follow-up was performed prospectively, and predefined criteria were applied to diagnose symptomatic VTE. Only a minority (0.6%) of the patients with a normal initial workup were lost to follow-up; although among the patients who completed the 3-month period of observation, approximately 75% were contacted by telephone and approximately 25% presented to the clinics for a clinical and instrumental evaluation. The latter finding may be regarded as a potential limitation, although telephone interviews quite commonly substitute for end-of-follow-up visits, especially when patients' samples are large.^{11,13,14} However, patients often fail to present for repeat testing, for various reasons.³⁴ Given that the characteristics of the study patients and the rate of both initial and long-term DVT were consistent with those reported by previous similar studies,^{3-8,11-14} our results are likely to be valid and generalizable.

In conclusion, both serial 2-point ultrasonography plus D-dimer and whole-leg color-coded Doppler ultrasonography represent reliable diagnostic options for the management of symptomatic patients with suspected DVT of the lower extremities. Either strategy may be chosen based on the clinical context, on the patients' needs, and on the available resources. The former is simple, convenient, and widely available but requires repeat testing in one-fourth of the patients. The latter offers a 1-day answer, desirable for patients

with severe calf complaints, for travelers, and for those living far from the diagnostic service, but is cumbersome, possibly more expensive, and may expose patients to the risk of (unnecessary) anticoagulation.

Author Affiliations: Department of Emergency and Accident Medicine, Civic Hospital, Conegliano, Italy (Dr Bernardi); Angiology Unit (Drs Camporese and Verlato), Department of Medical and Surgical Sciences (Drs Piccioli and Prandoni), and Department of Clinical and Experimental Medicine, Group of Clinical Epidemiology (Dr Noventa), University Hospital, Padua, Italy; Department of Vascular Medicine, Academic Medical Center, University of Amsterdam, Amsterdam, the Netherlands (Dr Büller); and Service of Haemostasis and Thrombosis, University Hospital, Palermo (Drs Siragusa and Anastasio); Center for Haemostasis and Thrombosis, Department of Emergency and Accident Medicine, Civic Hospital, Piacenza (Drs Imberti and Prati); Department of Emergency and Accident Medicine, S Giovanni Battista Hospital, Torino (Dr Berchio); Angiology Unit, Department of Internal Medicine, S Maria Nuova Hospital, Reggio Emilia (Dr Ghirarduzzi); Department of Angiology, Civic Hospital, Castelfranco Veneto (Dr Pesavento); Department of Medicine, Civic Hospital, Cosenza (Dr Bova); Department of Surgical Sciences, S Carlo Borromeo Hospital, Milan (Dr Maltempo); Department of Internal Medicine, Civic Hospital, Vittorio Veneto (Dr Zanatta); Department of Vascular Medicine, Villa Berica Hospital, Vicenza (Dr Cogo); Department of Internal, Cardiovascular and Geriatric Medicine, Policlinico "Le Scotte," Siena (Dr Cappelli); Angiology Unit, Civic Hospital, Faenza (Dr Bucherini); Department of Internal Medicine, Civic Hospital, Rovigo (Dr Cuppini), Italy.

Author Contributions: Drs Bernardi and Camporese had full access to all of the data in the study and take responsibility for the integrity of the data and the accuracy of the data analysis.

Study concept and design: Bernardi, Piccioli, Prandoni. **Acquisition of data:** Bernardi, Camporese, Siragusa, Imberti, Berchio, Ghirarduzzi, Verlato, Anastasio, Prati, Pesavento, Bova, Maltempo, Zanatta, Cogo, Cappelli, Bucherini, Cuppini.

Analysis and interpretation of data: Bernardi, Camporese, Büller, Imberti, Prati, Noventa, Prandoni. **Drafting of the manuscript:** Bernardi, Camporese, Büller, Berchio, Noventa, Prandoni.

Critical revision of the manuscript for important intellectual content: Bernardi, Camporese, Büller, Siragusa, Imberti, Ghirarduzzi, Verlato, Anastasio, Prati, Piccioli, Pesavento, Bova, Maltempo, Zanatta, Cogo, Cappelli, Bucherini, Cuppini, Noventa, Prandoni.

Statistical analysis: Bernardi, Noventa.

Administrative, technical, or material support: Bernardi, Camporese.

Study supervision: Bernardi, Camporese, Büller, Imberti, Verlato, Prati, Piccioli, Pesavento, Noventa, Prandoni.

Financial Disclosures: None reported.

Members of the Erasmus Study Group (Italy): Angiology Unit, University Hospital, Padua: Laura Zotta, MD, Francesca Franz, MD, Claudia Chiarion, MD, Mariateresa Nardi, MD, Giuseppe M. Andreozzi, MD; Service of Haemostasis and Thrombosis, University Hospital, Palermo: Alessandra Malato, MD, Lucio Lo Coco, MD, Glauco Milio, MD, Oreste Cormaci, MD; Center for Haemostasis and Thrombosis, Department of Emergency and Accident Medicine, Civic Hospital, Piacenza: Pietro Cavallotti, MD, Sergio Orlando, MD; Department of Emergency and Accident Medicine, S Giovanni Battista Hospital, Torino: Elio Rolfo, MD, Carlo Valenzano, MD; Angiology Unit, Department of Internal Medicine, S Maria Nuova Hos-

pital, Reggio Emilia: Matteo Iotti, MD, Maria L. Cat-tabiani, MD; Department of Angiology, Civic Hospital, Castelfranco Veneto: Adriana Visonà, MD, Francesca Salsa, MD, Antonio Pagnan, MD; Department of Medicine, Civic Hospital, Cosenza: Roberto Ricchio, MD, Alfonso Noto, MD; Department of Surgical Sciences, S Carlo Borromeo Hospital, Milan: Pier G. Settembrini, MD; Department of Internal Medicine, Civic Hospital, Vittorio Veneto: Massimo Santonastaso, MD, Domenico Mogno, MD; Department of Internal, Cardiovascular, and Geriatric Medicine, Policlinico "Le Scotte," Siena: Maurizio Bichi, MD, Francesca Maggi, MD; Department of Internal Medicine, Civic Hospital, Rovigo: Stefano Zamboni, MD; Department of Medical and Surgical Sciences, University, Padua: Ugo Baccaglioni, MD, Giuseppe Spreafico, MD.

Funding/Support: This study project was awarded to Dr Bernardi by Siset (Società Italiana per lo Studio dell'Emostasi e della Trombosi). The AGEN Biomedical Ltd (Brisbane, Australia) provided the D-dimer testing kits free-of-charge.

Role of the Sponsor: The AGEN Biomedical Ltd had no role in the design and conduct of the study, in the collection, analysis, or interpretation of the data, or in the preparation, review, or approval of the manuscript.

Previous Presentation: This study was presented in part as an oral communication at the XXIst Congress of the International Society on Thrombosis and Haemostasis; July 6-12, 2007; Geneva, Switzerland.

REFERENCES

- Mantoni M. Diagnosis of deep venous thrombosis by duplex sonography. *Acta Radiol.* 1989;30(6):575-579.
- Lensing AW, Prandoni P, Brandjes D, et al. Detection of deep-vein thrombosis by real-time B-mode ultrasonography. *N Engl J Med.* 1989;320(6):342-345.
- Heijboer H, Büller HR, Lensing AW, Turpie AG, Colly LP, ten Cate JW. A comparison of real-time ultrasonography with impedance plethysmography for the diagnosis of deep-vein thrombosis in symptomatic outpatients. *N Engl J Med.* 1993;329(19):1365-1369.
- Cogo A, Lensing AWA, Koopman MMW, et al. Compression ultrasonography for diagnostic management of patients with clinically suspected deep vein thrombosis: prospective cohort study. *BMJ.* 1998;316(7124):17-20.
- Birdwell BG, Raskob GE, Whitsett TL, et al. Predictive value of compression ultrasonography for deep vein thrombosis in symptomatic outpatients: clinical implications of the site of vein noncompressibility. *Arch Intern Med.* 2000;160(3):309-313.
- Tick LW, Ton E, van Voorthuizen T, et al. Practical diagnostic management of patients with clinically suspected deep vein thrombosis by clinical probability test, compression ultrasonography, and D-dimer test. *Am J Med.* 2002;113(8):630-635.
- Bernardi E, Prandoni P, Lensing AW, et al. D-dimer testing as an adjunct to ultrasonography in patients with clinically suspected deep vein thrombosis: prospective cohort study. *BMJ.* 1998;317(7165):1037-1040.
- Kraaijenhagen RA, Piovella F, Bernardi E, et al. Simplification of the diagnostic management of suspected deep vein thrombosis. *Arch Intern Med.* 2002;162(8):907-911.
- Jacoby J, Cesta M, Axelband J, Melanson S, Heller M, Reed J. Can emergency medicine residents detect acute deep venous thrombosis with a limited, two-site ultrasound examination? *J Emerg Med.* 2007;32(2):197-200.
- Wells PS, Anderson DR, Rodger M, et al. Evaluation of D-dimer in the diagnosis of suspected deep-

vein thrombosis. *N Engl J Med*. 2003;349(13):1227-1235.

11. Kearon C, Ginsberg JS, Douketis J, et al. A randomized trial of diagnostic strategies after normal proximal vein ultrasonography for suspected deep venous thrombosis: D-dimer testing compared with repeated ultrasonography. *Ann Intern Med*. 2005;142(7):490-496.

12. Elias A, Mallard L, Elias M, et al. A single complete ultrasound investigation of the venous network for the diagnostic management of patients with a clinically suspected first episode of deep venous thrombosis of the lower limbs. *Thromb Haemost*. 2003;89(2):221-227.

13. Schellong SM, Schwarz T, Halbritter K, et al. Complete compression ultrasonography of the leg veins as a single test for the diagnosis of deep vein thrombosis. *Thromb Haemost*. 2003;89(2):228-234.

14. Stevens SM, Elliott CG, Chan KJ, Egger MJ, Ahmed KM. Withholding anticoagulation after a negative result on duplex ultrasonography for suspected symptomatic deep venous thrombosis. *Ann Intern Med*. 2004;140(12):985-991.

15. El Kheir D, Büller HR. One-time comprehensive ultrasonography to diagnose deep venous thrombosis: is that the solution? *Ann Intern Med*. 2004;140(12):1052-1053.

16. Anderson DR, Wells PS, Stiell I, et al. Thrombosis in the emergency department: use of a clinical diagnosis model to safely avoid the need for urgent radiological investigation. *Arch Intern Med*. 1999;159(5):477-482.

17. Blaivas M. Ultrasound in the detection of venous thromboembolism. *Crit Care Med*. 2007;35(5)(suppl):S224-S234.

18. Gaitini D. Current approaches and controversial

issues in the diagnosis of deep vein thrombosis via duplex doppler ultrasound. *J Clin Ultrasound*. 2006;34(6):289-297.

19. Zierler BK. Ultrasonography and diagnosis of venous thromboembolism. *Circulation*. 2004;109(12)(suppl 1):I9-I14.

20. Imberti D, Ageno W, Dentali F, Giorgi Pierfranceschi M, Croci E, Garcia D. Management of primary care patients with suspected deep vein thrombosis: use of a therapeutic dose of low-molecular-weight heparin to avoid urgent ultrasonographic evaluation. *J Thromb Haemost*. 2006;4(5):1037-1041.

21. Righini M, Paris S, Le Gal G, Laroche JP, Perrier A, Bounameaux H. Clinical relevance of distal deep vein thrombosis: review of literature data. *Thromb Haemost*. 2006;95(1):56-64.

22. Bounameaux H, Righini M, Perrier A. Diagnosing deep vein thrombosis: the case for compression ultrasonography limited to the proximal veins. *J Thromb Haemost*. 2004;2(12):2260-2261.

23. Hull RD. Revisiting the past strengthens the present: an evidence-based medicine approach for the diagnosis of deep venous thrombosis. *Ann Intern Med*. 2005;142(7):583-585.

24. Righini M, Bounameaux H, Le Gal G. Single complete compression ultrasonography for suspected deep venous thrombosis: ideal in routine clinical practice? *Ann Intern Med*. 2004;141(11):888-889.

25. Lagerstedt CI, Olsson CG, Fagher BO, Oqvist BW, Albrechtsson U. Need for long-term anticoagulant treatment in symptomatic calf-vein thrombosis. *Lancet*. 1985;2(8454):515-518.

26. Wells PS, Brill-Edwards P, Stevens P, et al. A novel and rapid whole-blood assay for D-dimer in patients with clinically suspected deep vein thrombosis. *Circulation*. 1995;91(8):2184-2187.

27. Lewis BD, James EM, Welch TJ, Joyce JW, Hallet JW, Weaver AL. Diagnosis of acute deep venous thrombosis of the lower extremities: prospective evaluation of color Doppler flow imaging versus venography. *Radiology*. 1994;192(3):651-655.

28. Baxter GM, Duffy P, Partridge E. Colour flow imaging of calf vein thrombosis. *Clin Radiol*. 1992;46(3):198-201.

29. Newcombe RG. Interval estimation for the difference between independent proportions: comparison of eleven methods. *Stat Med*. 1998;17(8):873-890.

30. Kearon C, Kahn SR, Agnelli G, Goldhaber S, Raskob GE, Comerota AJ. Antithrombotic therapy for venous thromboembolic disease: American College of Chest Physicians Evidence-Based Clinical Practice Guidelines (8th edition). *Chest*. 2008;133(6)(suppl):454S-545S.

31. Kraaijenhagen RA, Lensing AWA, Lijmer JG, et al. Diagnostic strategies for the management of patients with clinically suspected deep-vein thrombosis. *Curr Opin Pulm Med*. 1997;3(4):268-274.

32. Cogo A, Lensing AWA, Prandoni P, Hirsh J. Distribution of thrombosis in patients with symptomatic deep vein thrombosis: implications for simplifying the diagnostic process with compression ultrasound. *Arch Intern Med*. 1993;153(24):2777-2780.

33. Kearon C, Ginsberg JS, Douketis J, et al. Management of suspected deep venous thrombosis in outpatients by using clinical assessment and D-dimer testing. *Ann Intern Med*. 2001;135(2):108-111.

34. McIlrath ST, Blaivas M, Lyon M. Patient follow-up after a negative lower extremity bedside ultrasound for deep venous thrombosis in the ED. *Am J Emerg Med*. 2006;24(3):325-328.